

# **Predictive Homoeopathy®**

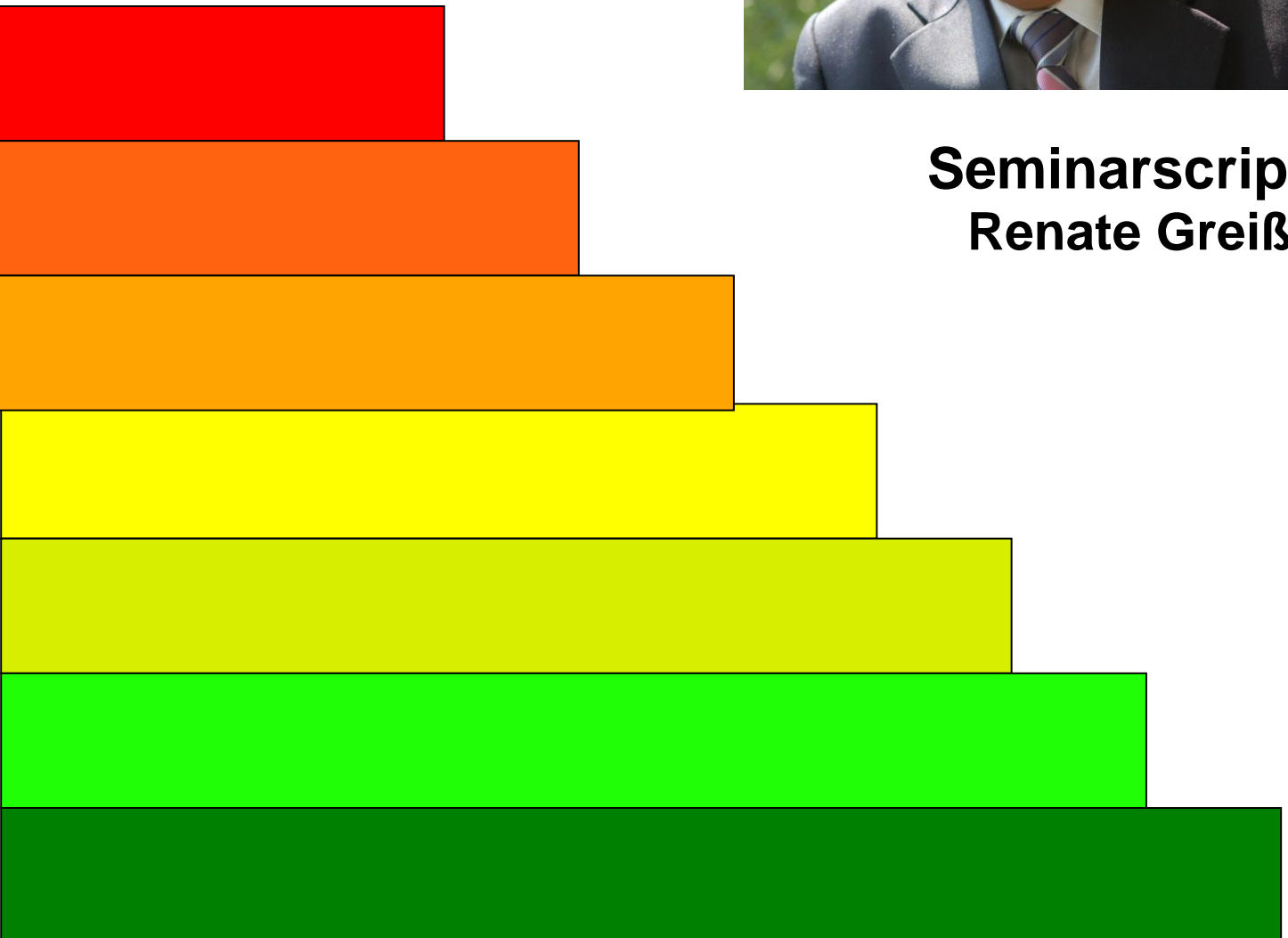
**Dr. Prafull Vijayakar**

**Gauting, Juli 2006**

**München, November 2008**

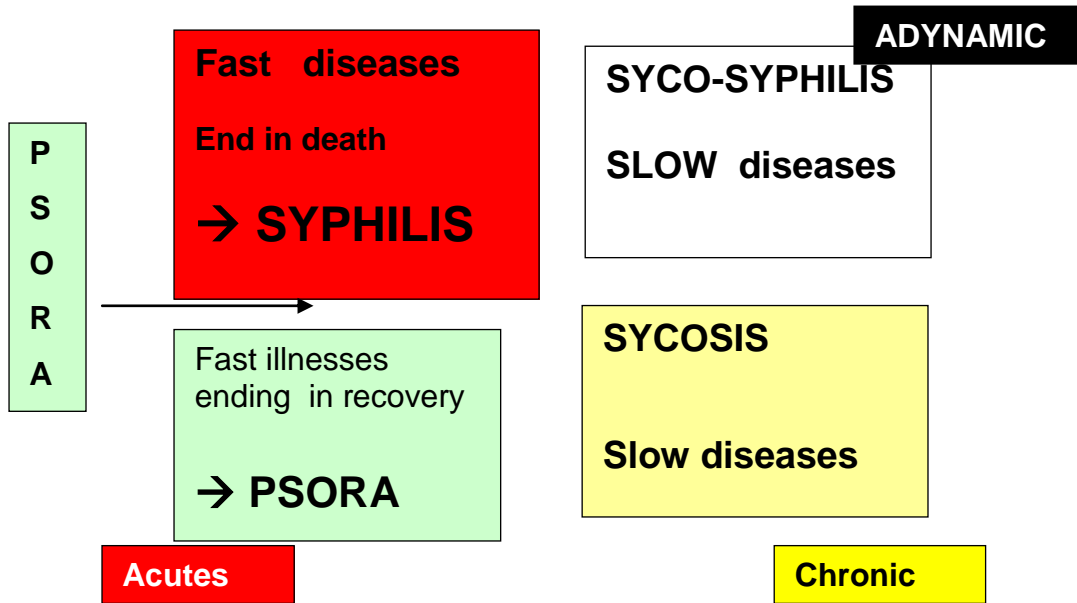


**Seminarscript  
Renate Greißl**



## Contents – Seminar 2006

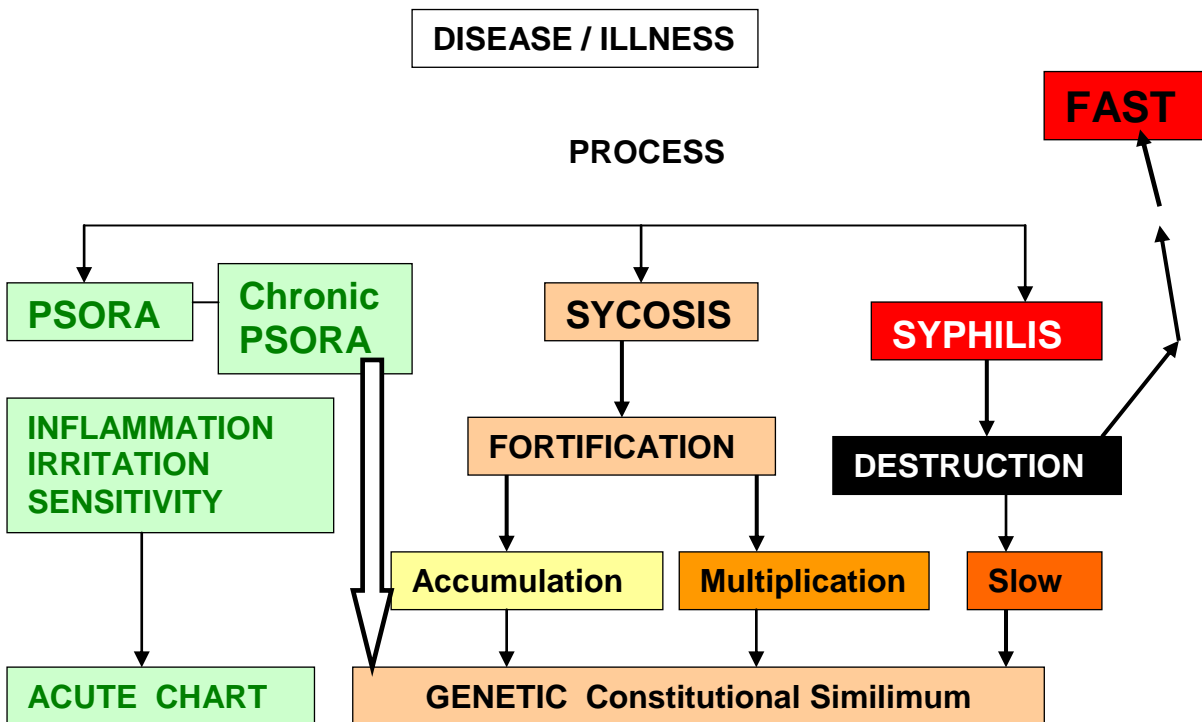
	Page
<b>14.07.2006</b>	
Philosophical thoughts	1
Case 1 – Pain in Abdomen, vomiting – Sepia	3-8
Rubric – Ailments from long domination – Differentiation	4
Pain – Differentiation	7
Case 2 – ALL – Lachesis	9
Causes and Miasm	12
Case 3 – Renal Failure, Emergency – Nux-v	13
<b>15.07.2006</b>	
Treatment of high blood pressure	15
Theory – Disease – Miasm	17
Case 4 – Delayed Milestones – Mercurius	21
Case 5 – Medulloblastom – Platina	24
Theory – Virus	29
Case 6 – Retinopathy – Phosphorus	30
<b>16.07.2006</b>	
Case 7 – Arachnoid-Cyst of spine - Silica	34
Case 8 – Carbo-Monoxyd-Poisoning – Aethusa	38
Case 9 – Subdural Haematoma – Lycopodium	41
Case 10 – Coma - Stramonium	43
Case 11 – Parkinson Disease – Aurum	45
Case 12 – Aplasia of fingers	46



Way from dynamic psora → dynamic sycosis accumulation  
 → solid sycosis multiplication → syphilitic, last state slow

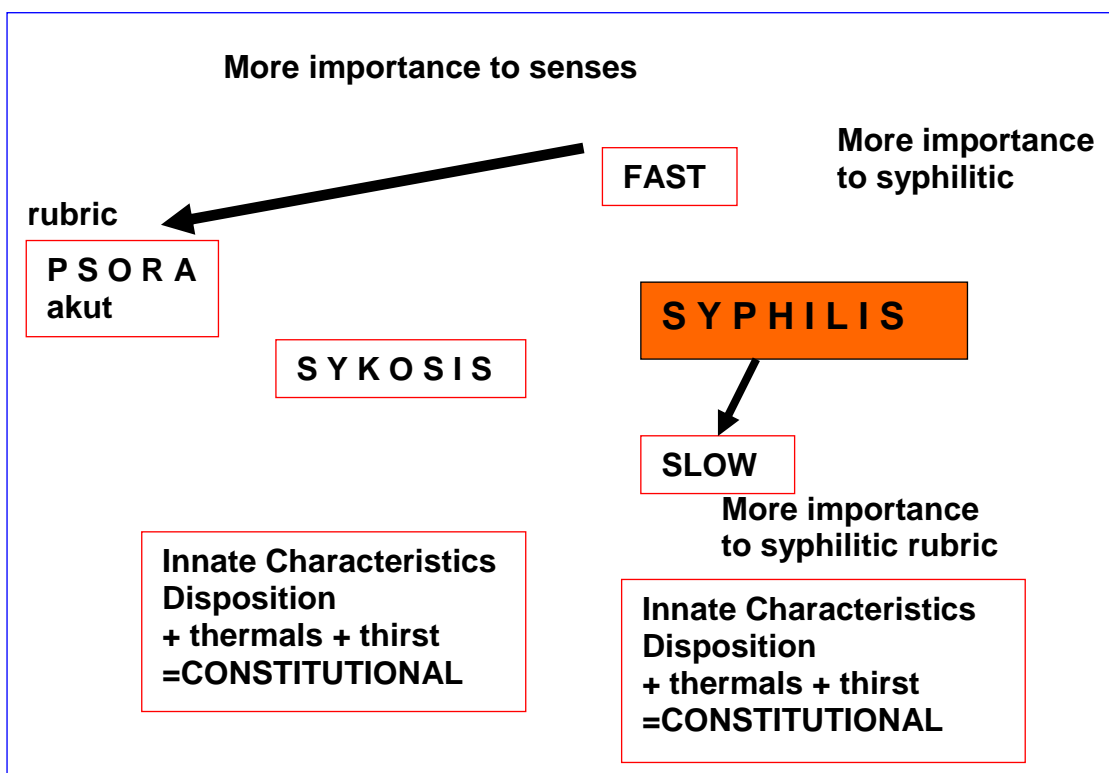
### Defence Mechanism of living body (physical)

Psora	Sycosis		Syphilis	
	↓	↓	↓	↓
All inflammatory disorders	Accumulative (dynamic)	Proliferative (adynamic)	slow (all autoimmune diseases)	fast
Dermatitis Conjunctivitis Bronchitis Gastritis Pancreatitis Vaginitis Convulsion-febrile Colics	<u>Excess:</u> Hyper-glycaemia -cholestrolaemia -lipidaemia -melanosis -pigmentation -tension (stress) Glaucoma Cysts, stones Contracture / Strictures Induration of organs  <u>Less:</u> Dilatation of organs Relaxation – Hernias, Ptosis	Benign tu Polyps Fibroids Psoriasis-scales Warts Arteriosclerosis Hypertension (chron.)	- Rheumatoid arthritis - Hashimotos thyroid - Psoriasis-cracks - Alzheimer dis. - Parkinsonism - MS  Chronic: - Leukaemia - Renal failure  - Motoneurone diseases	- Epilepsy degn. - Pneumonia - Cardiac, brain infarct - Anaphylaxis - Acute meningitis - Acute renal failure - Acute leukaemia



- As long as the process is slow = constitutional treatment
- If the process is fast – (psora meets syphilitic – extreme combination)
  - “Catch the gun first” means: treat the dangerous symptoms first

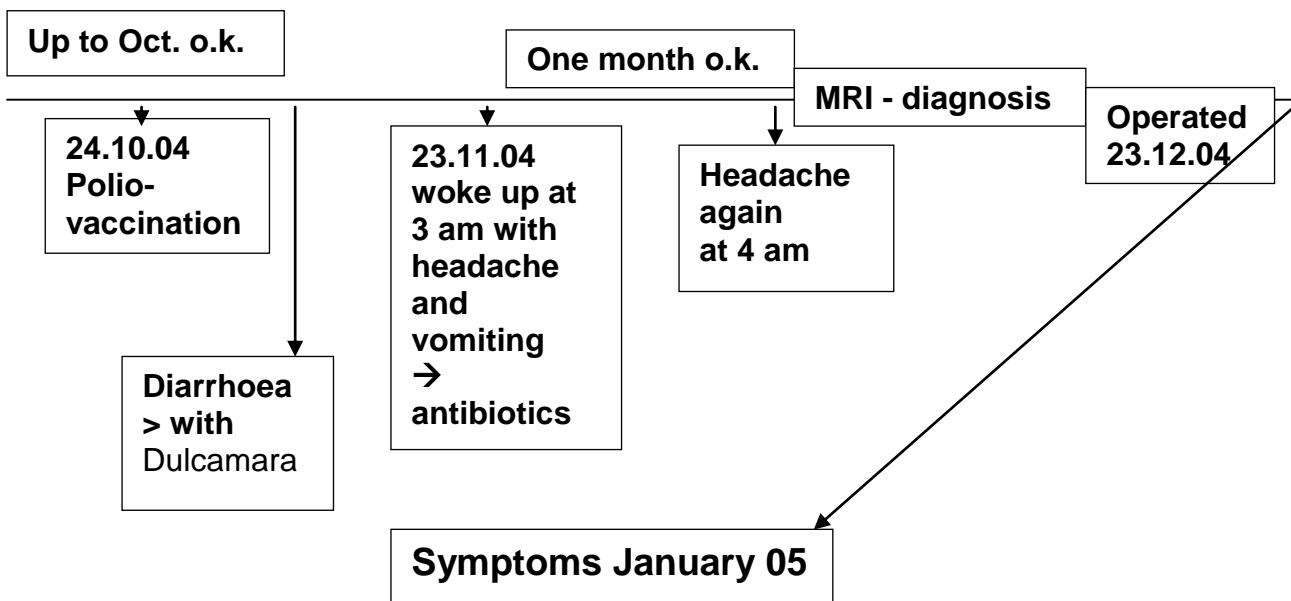
When psora +syphilitic join together → a fast, dynamic, destructive disease will be the result! → Terrible!!



## Case 5

Case of Medulloblastoma 1-05  
Girl aged 4 years – operated in 12-04  
Relapse  
Symptoms 1-05:  
Cannot see  
Cannot talk  
Cannot rise  
Cannot walk

Child was crying – legs has to be bent, when stretched she starts crying  
24.10. Vaccination polio → diarrhoea (got Dulcamara)  
13.11. Woke up at 3 am with headache and vomiting > with painkiller  
→ one month o.k.  
Then headache again at 4 am in morning  
MRI – diagnosis Medulloblastoma → operated at 23.12.04



### Present Complaint:

Pain in both lower limbs after surgery  
Cannot sit, cannot walk, cannot lie on her back, she loses her balance & falls  
Residual headaches worse at night disturbing sleep.  
Has to lie on her parents abdomen.  
Headaches < inside a room where there are many people around  
Headaches > by going in open air  
Pain more on left leg.  
She cannot speak since surgery; she was better before surgery, she could talk. She could walk before surgery. Difficulty in chewing; has to be fed liquids.

# Contents – Seminar 2008

	Page
<b>22.11.2008</b>	
Case 1 – Swelling and Induration of eye – Sulphur	1
Case 2 – Burn after Explosion – Mag-sulph	2
Case 3 – Burn on face, firecracker – Palladium	4
Case 4 – Knock-Knees – Pulsatilla	6
Case 5 – Recurrent abdominal pain – Ignatia	8
Case 6 – Astrocytoma – Manganum	13
Case 7 – West-Syndrome – Mercurius	17
<b>23.11.2008</b>	
Case 8 – Alopecia universalis – Mag-mur	18
Case 9 – Cerebellar Ataxia – Plumbum	22
Case 10 – Acute-respiratory-distress-syndrome – Arsenic	26
Case 11 – Chromosome based Infertility – Lycopodium	27
Case 12 – Retarded Child, Spastic – Opium	28
Case 13 – Retarded Child, Spastic – Hyoscyamus	30
Case 14 – Anxiety – Pulsatilla	32
Case 15 – Haemophilie – Crot-h. / Phos	32
Case 16 – Arrhythmia, blue leg – Elaps	32
Case 17 – Aplasia of fingers – Opium	33

## Case 7

A Child, 18 months of age, was brought with diagnosis of West Syndrome.

At the age of 6 months the child was normal:

He used to hold his head properly;

He used to slide on abdomen in reverse direction;

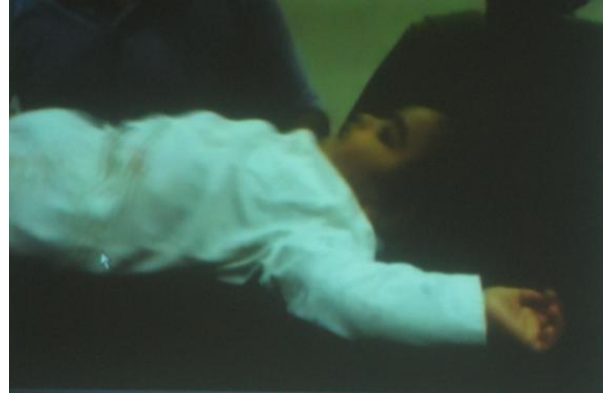At age of 6 months the child was vaccinated!

He then started getting jerks, 20 times a day. Child specialist was consulted and after investigations was diagnosed as West syndrome (Lightning attacks, Salaam attacks).

Till 6 month everything was fine, convulsions started

Lot of vaccination was given before;

The child cannot hear anything, no smiling, no reaction. (West-syndrom often goes to autism)



West syndrom (see Wikipedia)

- Cause is still unknown; There is some biochemical disturbance that is responsible for gradual destruction of brain and its faculties
- There is no chance of reversal of destruction and no chance of leading a normal life

The child was seen to have more force and power in the thighs, body was growing and mind was not → Bufo 200 → no result

### Re-Analysis of this case was done in 9-08

- The child is very restless (Striking is not important esp. when the brain is damaged, it is like an animal – important is only what belongs to the child)
- Relaxation of muscles
- Hunger cannot tolerate = weakness
- Vaccination agg.

	Merc	Sulph	Ant-t	Ars
W	7	9	4	5
H	4	4	3	3
E	3	1	1	1
U	1	2	1	2
C	1	3		
S	2	3	2	2

RESTLESSNESS, children, in  
RELAXATION Muscles  
WEAKNESS, enervation, exhaustion, prostration, infirmity hunger  
VACCINATION after

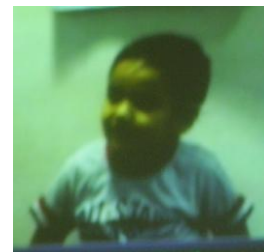→ **Merc 200** (strength in restlessness) given 9/08

### FU 11/08

He sits alone on the table,

He is strong;

Starts walking, interaction possible, demanding,



Now he has come to his own, first he was only existing, now he is living!

General tendencies PV gives maximum importance to:  
Discoloration  
Haemorrhages